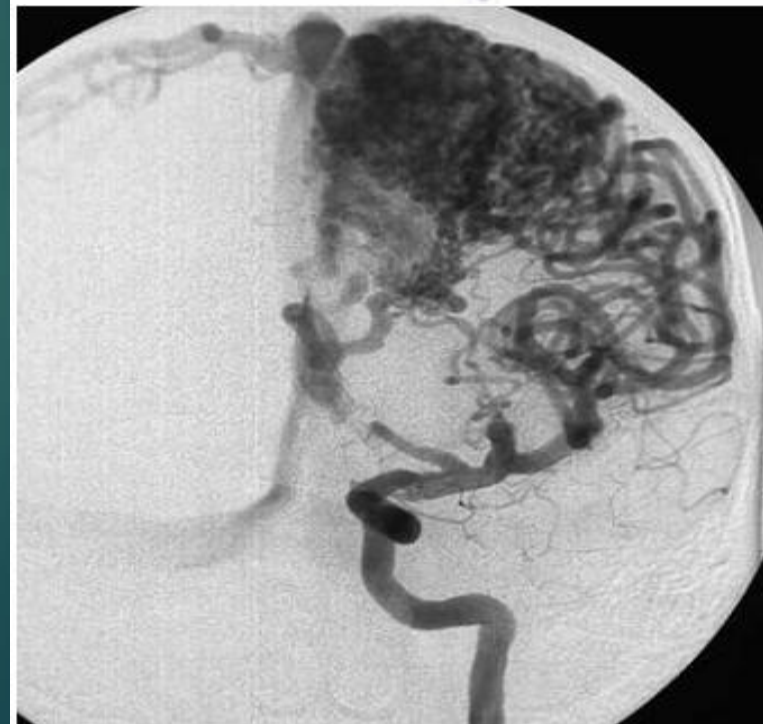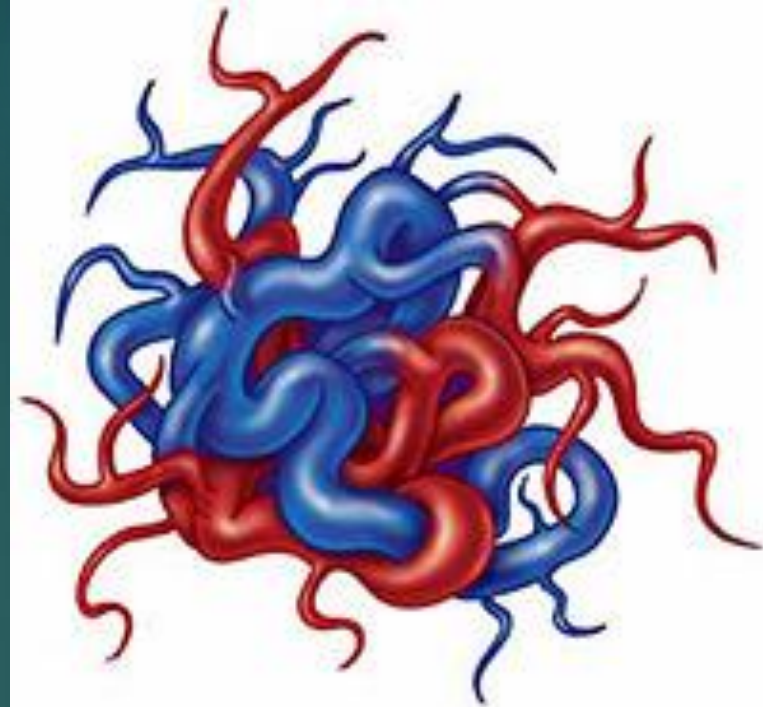

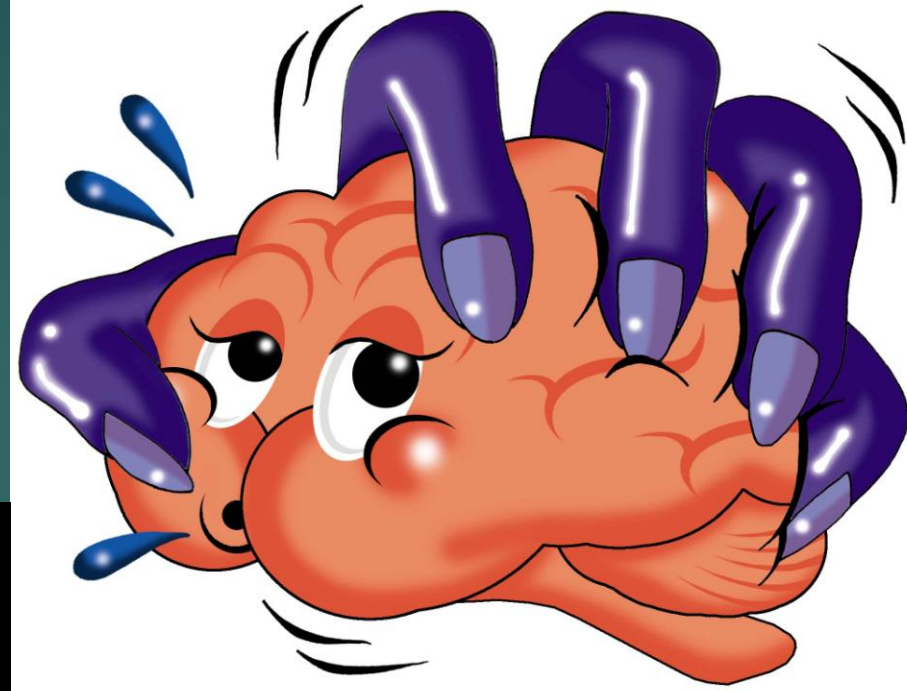
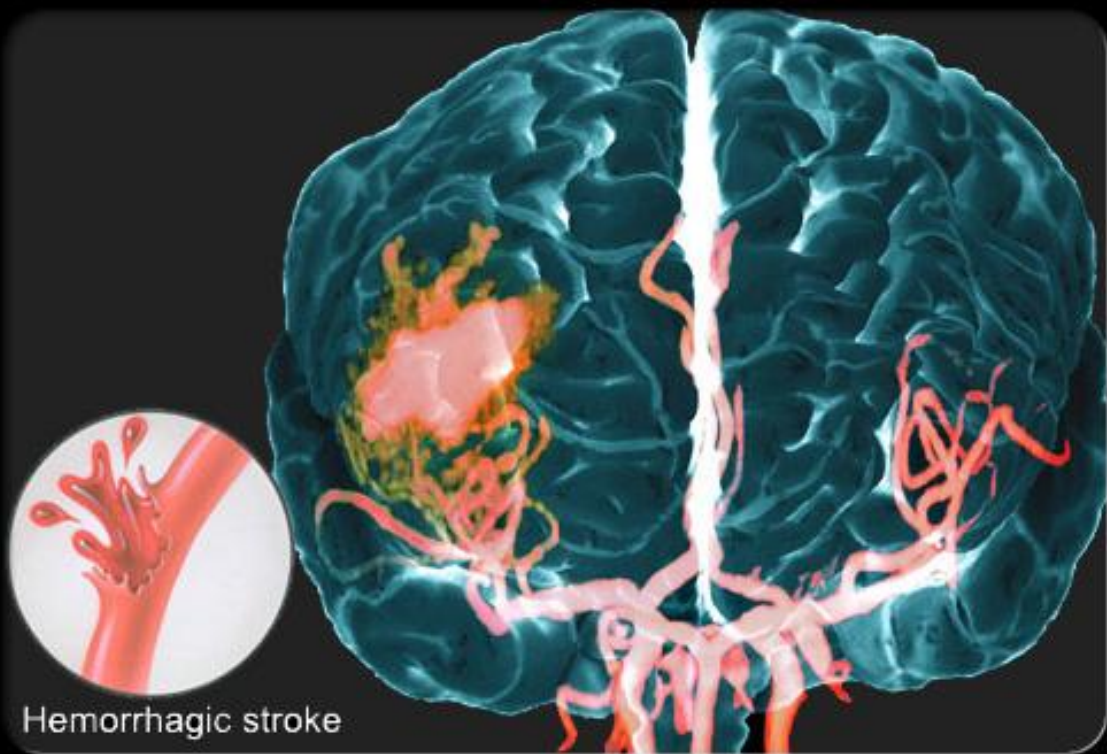Endovascular Treatment of Cerebral Arteriovenous Malformations

*Bs. Nguyễn Ngọc Pi Doanh- Bs Đặng Ngọc Dũng
– Khoa Ngoại Thần Kinh*



Stroke



Vascular Malformations of the Brain

Table 9.1 Classification of Chaloupka and Huddle [9]

Benign proliferating vascular anomalies: Haemangioma

Nonproliferating vascular anomalies:

Capillary malformation [telangiectasias]

Venous malformation

Cavernous malformation [cavernoma]

Arterial malformation [angiodysplasia and aneurysm]

Arteriovenous shunting malformation

Brain AVM

Brain AVF

Dural AVM

Vein of Galen AVF

Mixed malformation

Fig 1: normal connections between arteries and veins via capillary beds

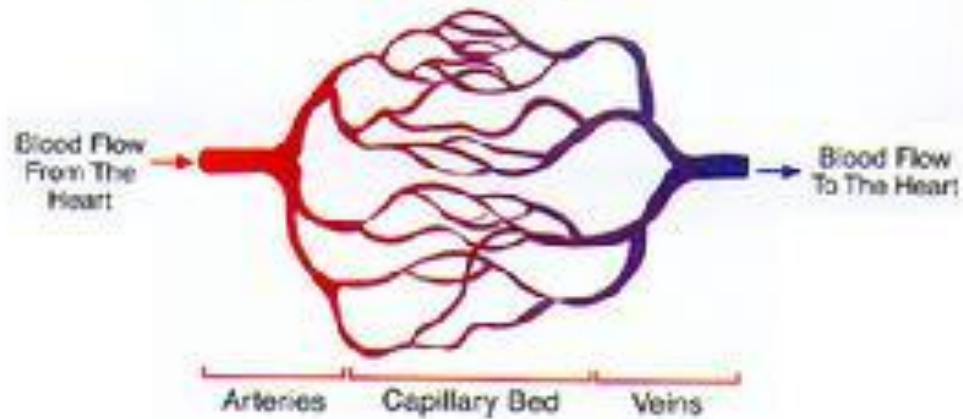
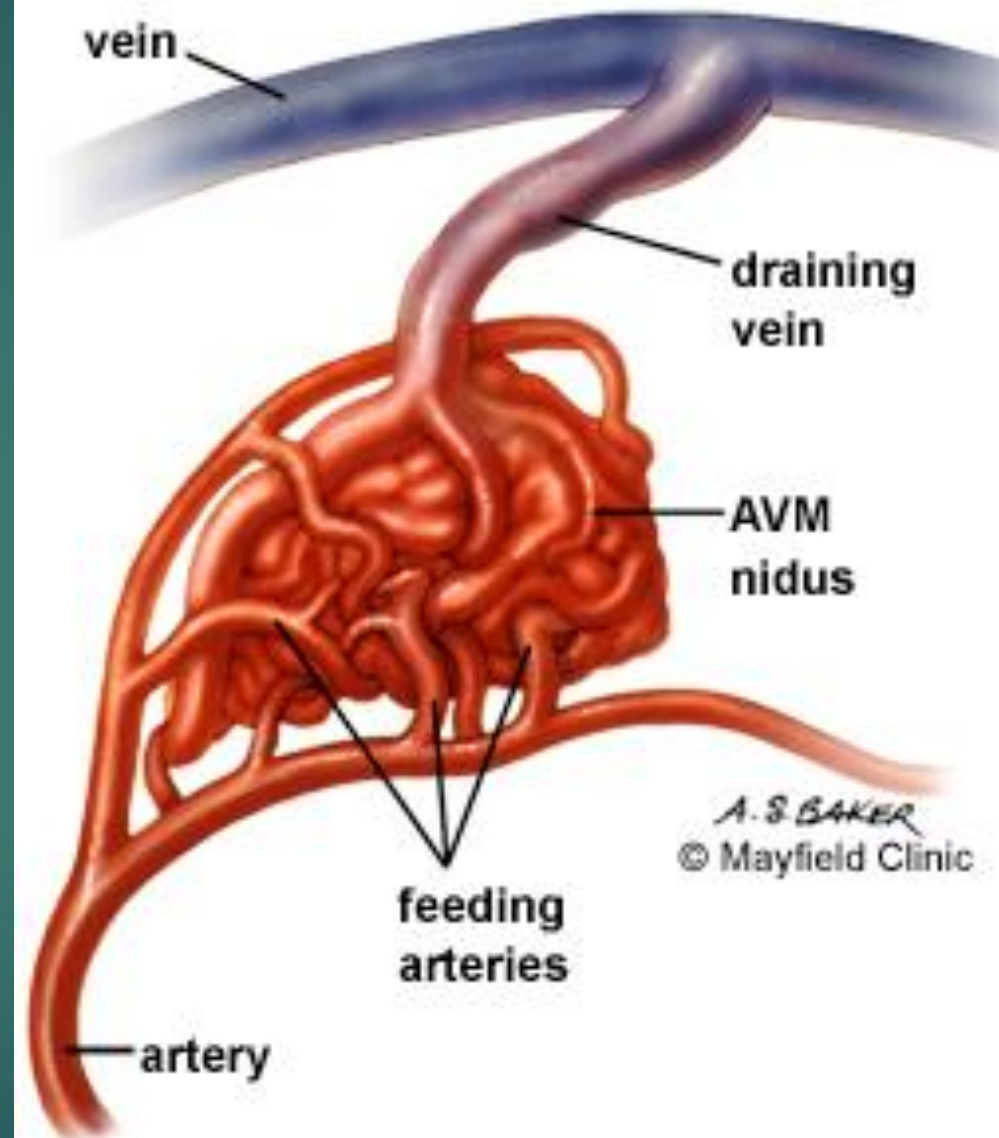
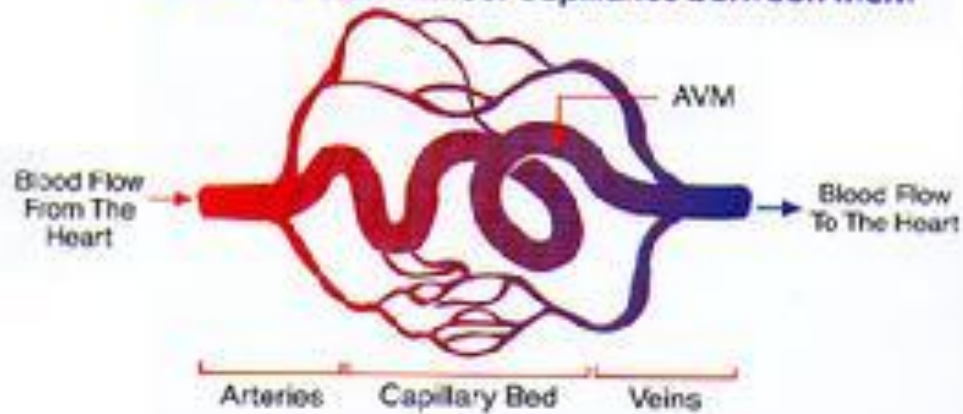


Fig. 2: AVM-abnormal connections between arteries and veins exist without capillaries between them



Epidemiology:

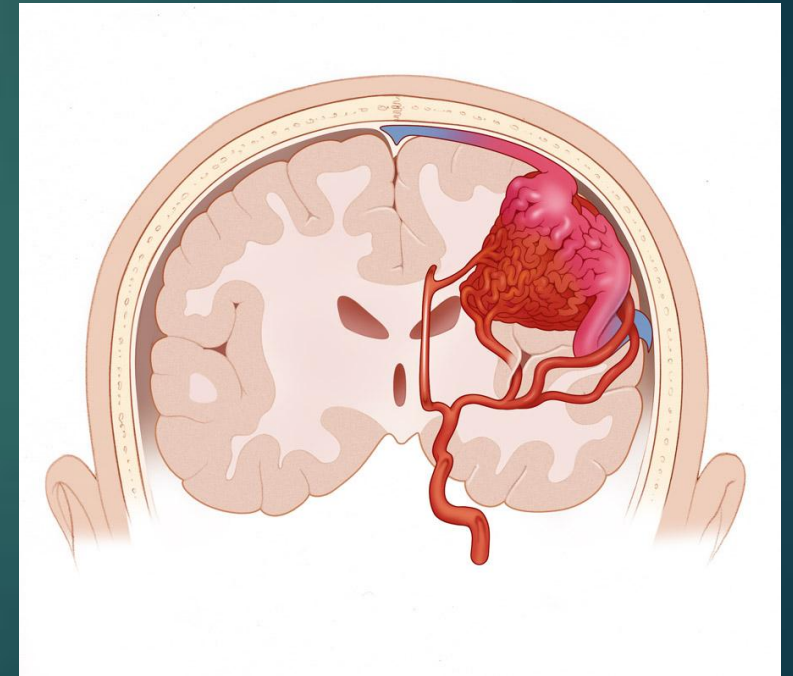
- Incidence: 0.1%, (1/10 intracranial aneurysms), 90% supratentorial lesions.
- 1- 2% of all strokes, 3% of strokes in young adults, and 9% of subarachnoid hemorrhages.

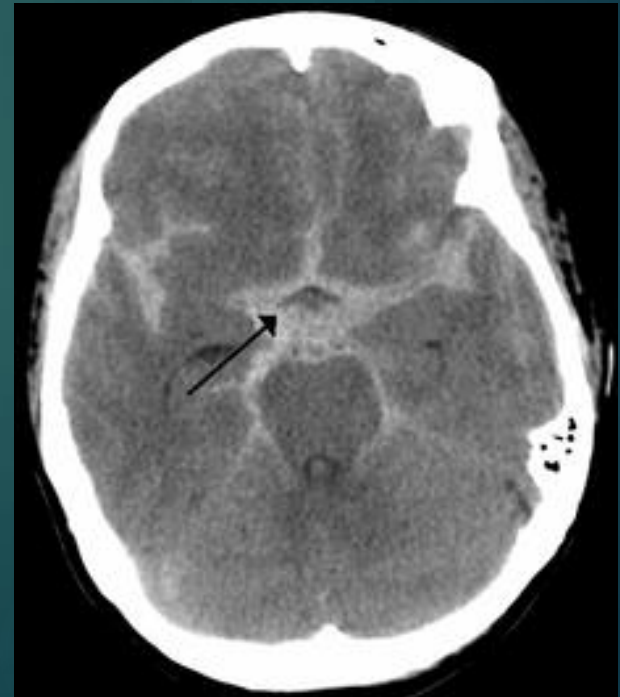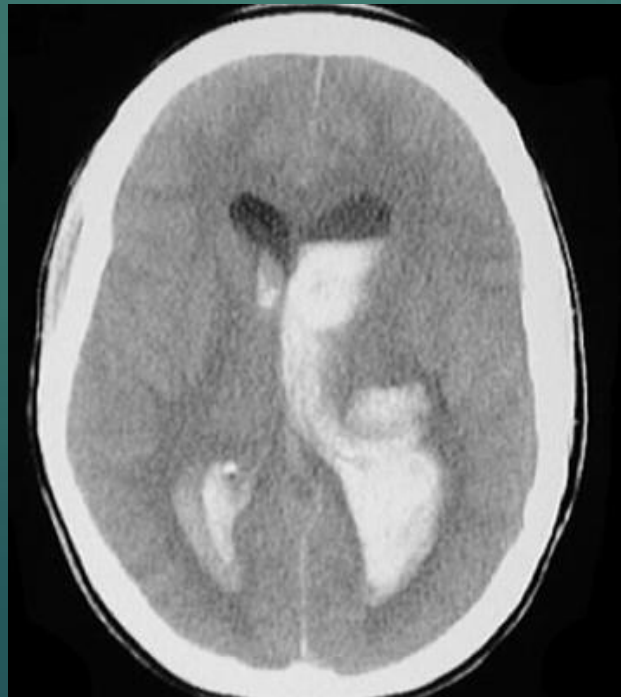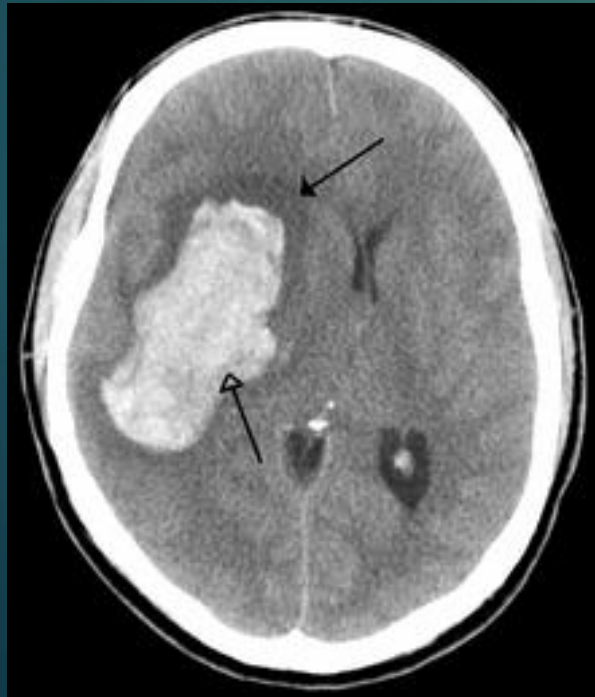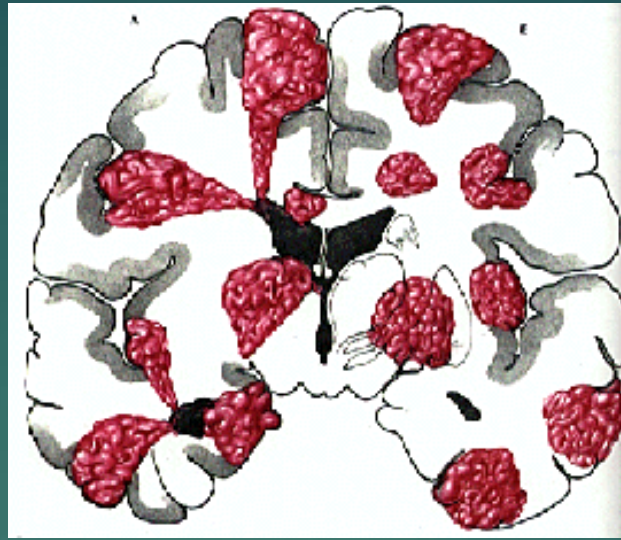
Clinical presentation:

- Intracranial hemorrhage: > 50% (ICH, SAH, IVH)
- Seizure: 20- 25%
- Headache: 15 %.
- Focal neurological deficit: 5%

Children < 2 years:

- Congestive heart failure
- Hydrocephalus.
- Seizure.
- *Auscultation of the skull (+) : 50%*





Risk of hemorrhage

- Annual risk of bleeding: 2-4%
- Risk of recurrent intracranial hemorrhage: first year ↑ 6-18%

Lifetime risk (%) = 105 – the patient's age in years.

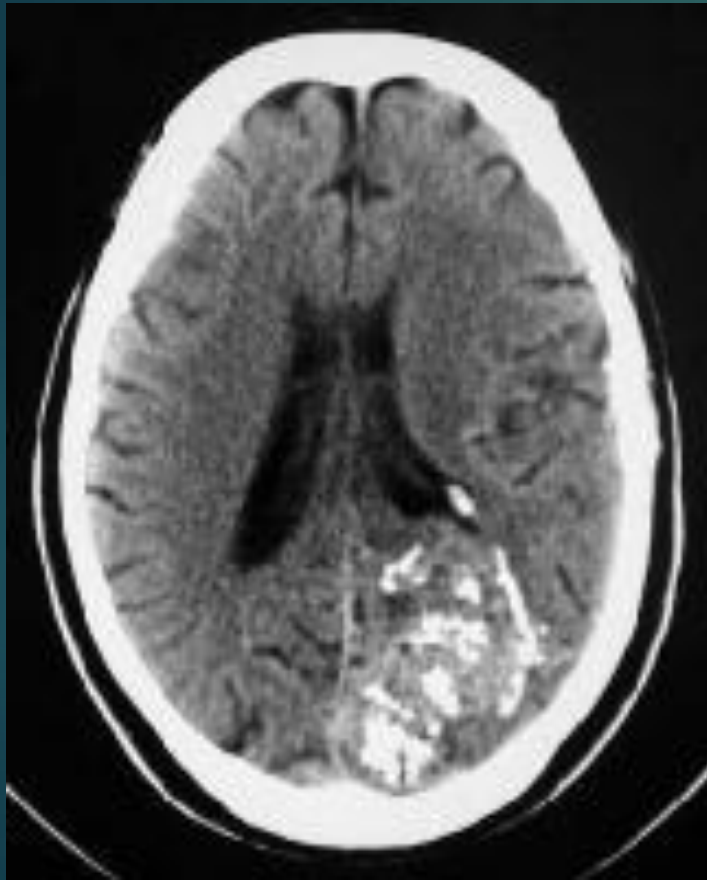
- Mortality from the first hemorrhage: 10- 30%,
- Long-term disability: 10- 20%

Predictive of hemorrhage risk :

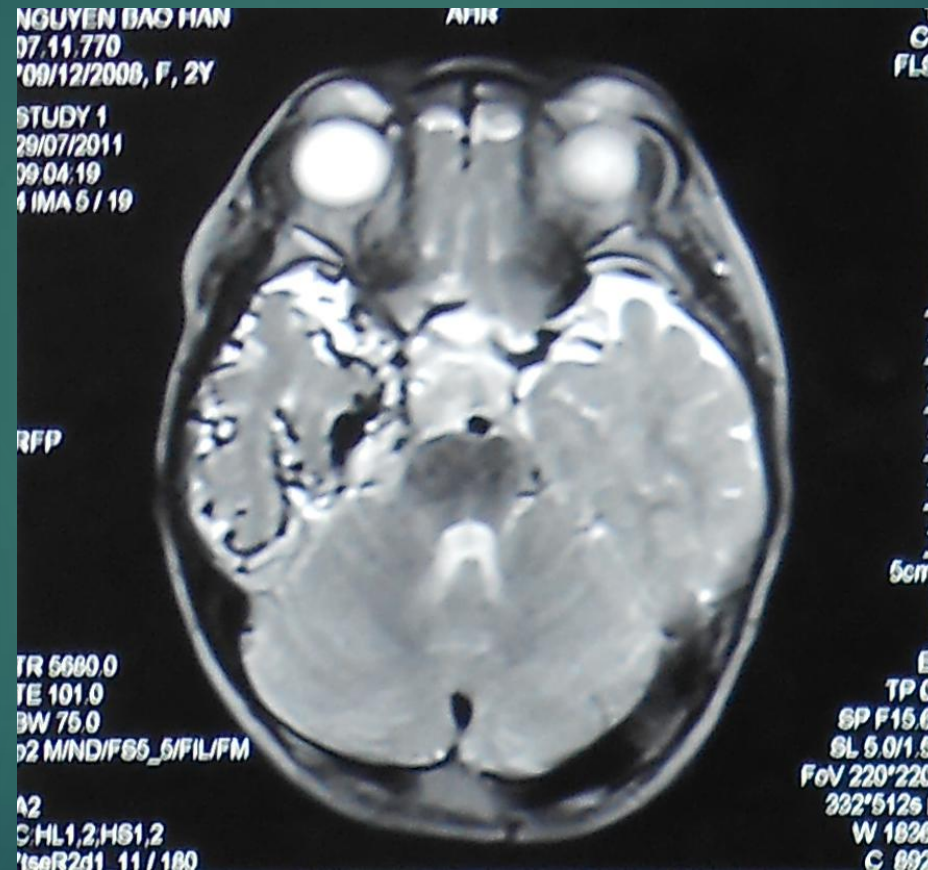- Feeding artery.
- Location: periventricular, intraventricular
- Venous drainage.
- Intranidal aneurysm
- Seizure.
- Prior hemorrhage
- Size, volume.

Diagnostic Imaging:

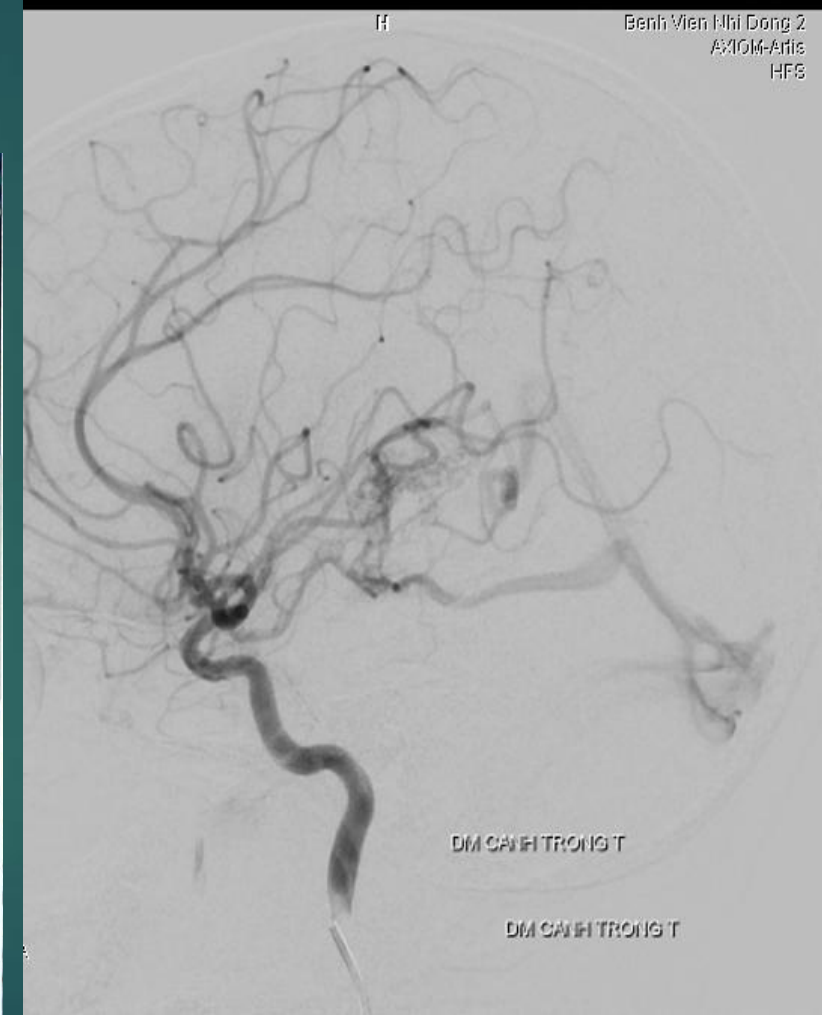
CT Scan



MRI



Angiography



Imaging strategy is closely related to the clinical presentation (rupture of the AVM or not) and the clinical status of the patient

Classification

TABLE 3. Spetzler-Martin AVM Grading Scale

Size	
0–3 cm	1
3.1–6.0 cm	2
>6 cm	3
Location	
Noneloquent	0
Eloquent	1
Deep venous drainage	
Not present	0
Present	1

- Predict surgical outcome.
- Evaluate the combined management.

Treatment-associated morbidity:

- Grade I,II, III: low
- Grade IV: 31,2%
- Grade V: 50%

Treatment:

Is treatment of unruptured AVMs beneficial?

Benefits

Risks

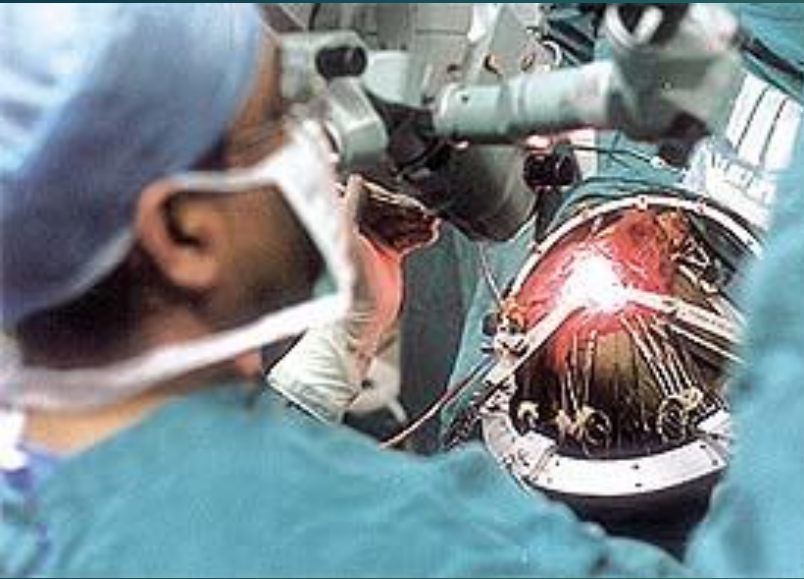

Crowford : (symtomatic AVM-10,4years)

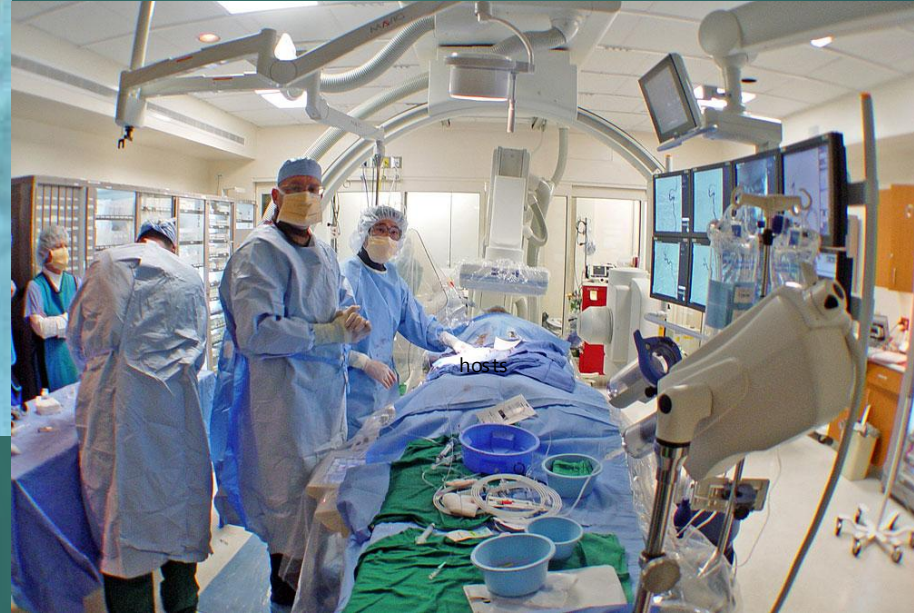- *Rish of Hemorrhage: 42%*
- *Rish of Dead: 29%*
- *Rish of Neurological Deficits : 27%*
- *Rish of Epilepsy: 18%*

▶ **A Randomized Trial of Unruptured Brain Arteriovenous Malformations (ARUBA)-NINDS**

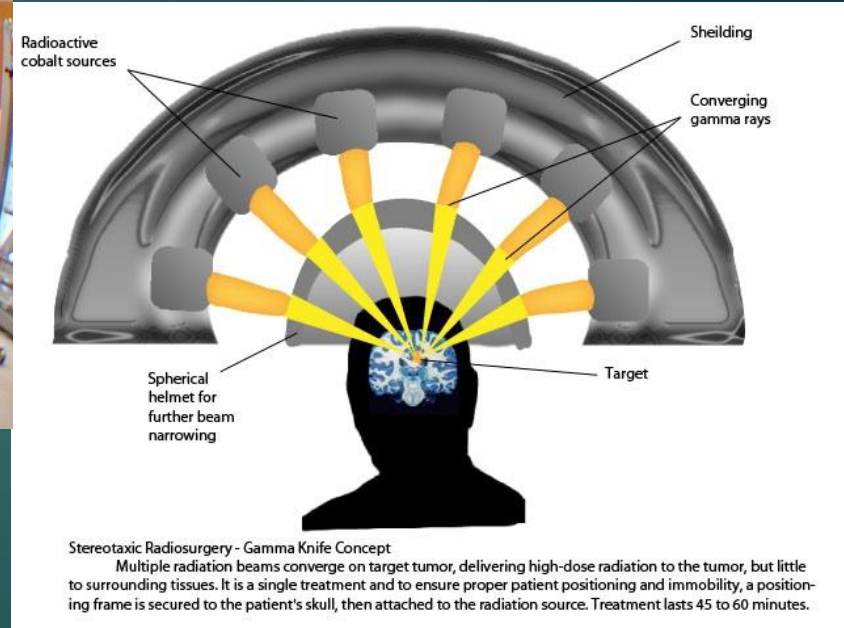
Treatment:



Microsurgery



Endovascular embolization



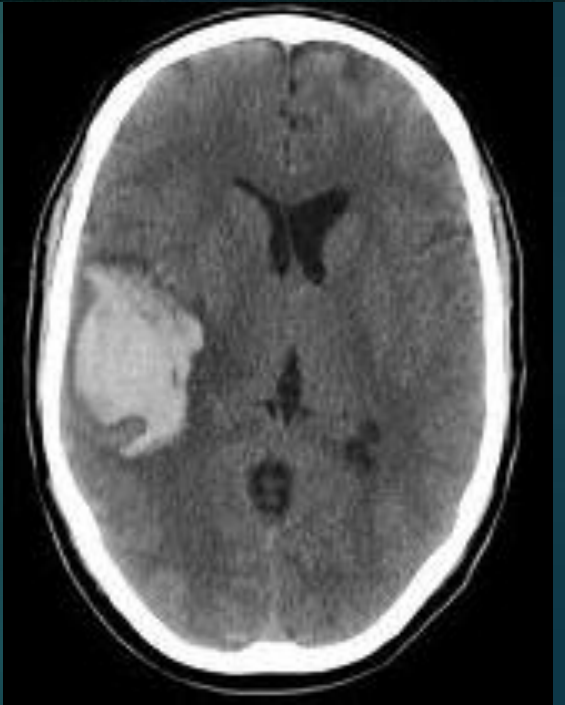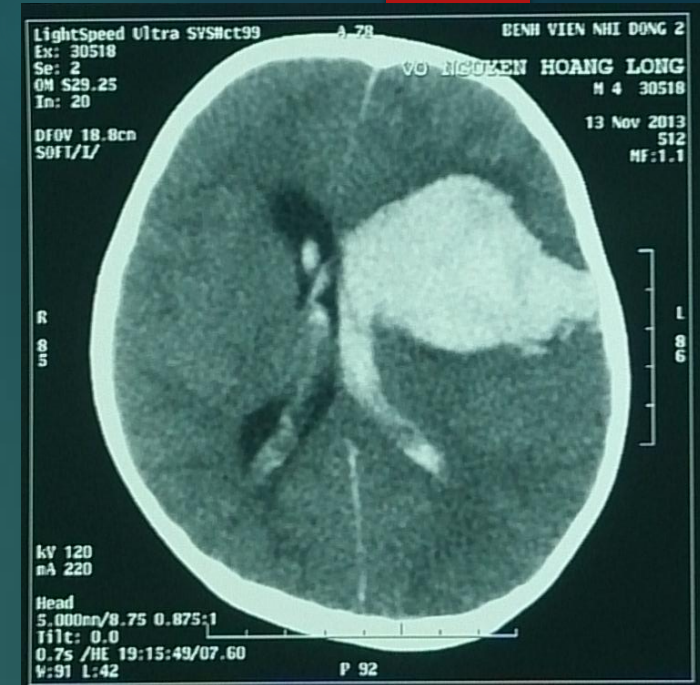
Stereotactic radiosurgery

Direct Surgical Treatment

- Emergency.
- Nonemergency: elective operation.

Outcome:

- Grade I-II: > 90% good
- Grade III: 68,2% (short time)- 88,6% (long time) .
- Grade IV: 73%
- Grade V: 57,1% - 14,3% poor outcome- 4,8% mortality.



Radiosurgery

- An important treatment technique.
- Appropriate for small AVMs, located in eloquent brain locations. Lesions most effectively treated with radiosurgery have volumes $<10 \text{ cm}^3$ or maximum diameter $<3 \text{ cm}$.
- Postsurgical or postembolized small residual AVMs or in patients who are not good candidates for surgery or refuse surgical treatment

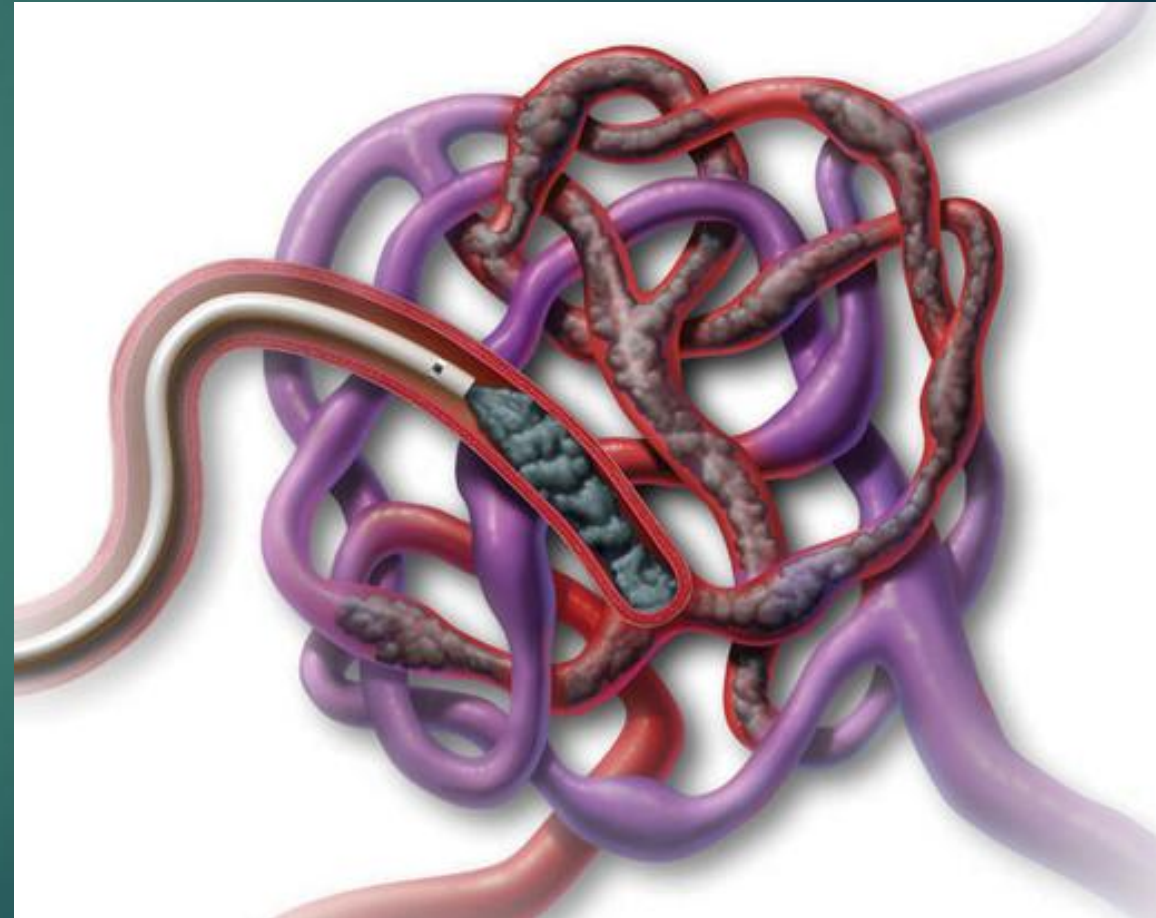
Endovascular Treatment :

1. **Preoperative**: embolization as a precursor to complete curative surgical resection;
2. **Targeted therapy**: embolization to eradicate a specific bleeding source;
3. **Preradiosurgery**: embolization as a precursor to radiation therapy;
4. **Curative**: embolization for attempted cure;
5. **Palliative**: embolization to palliate symptoms attributed to shunting

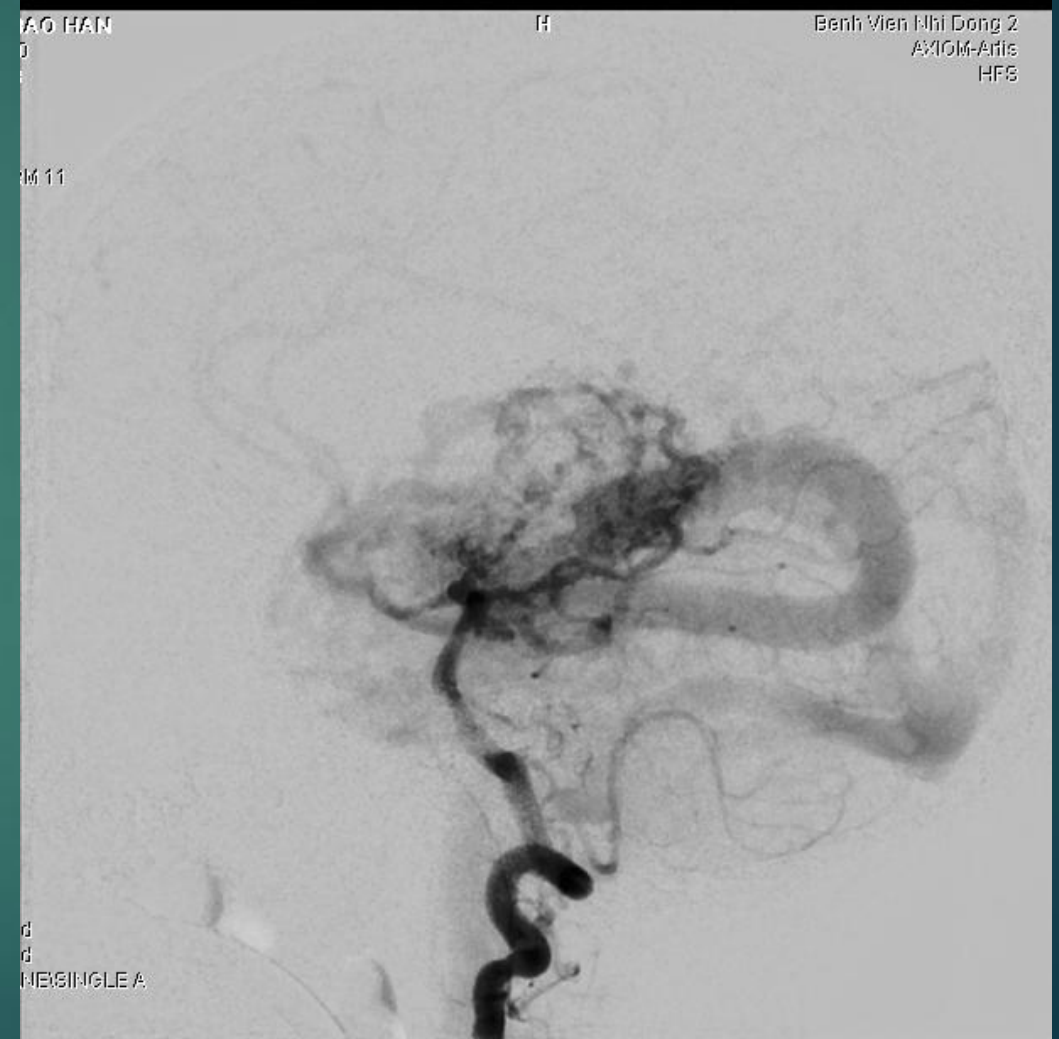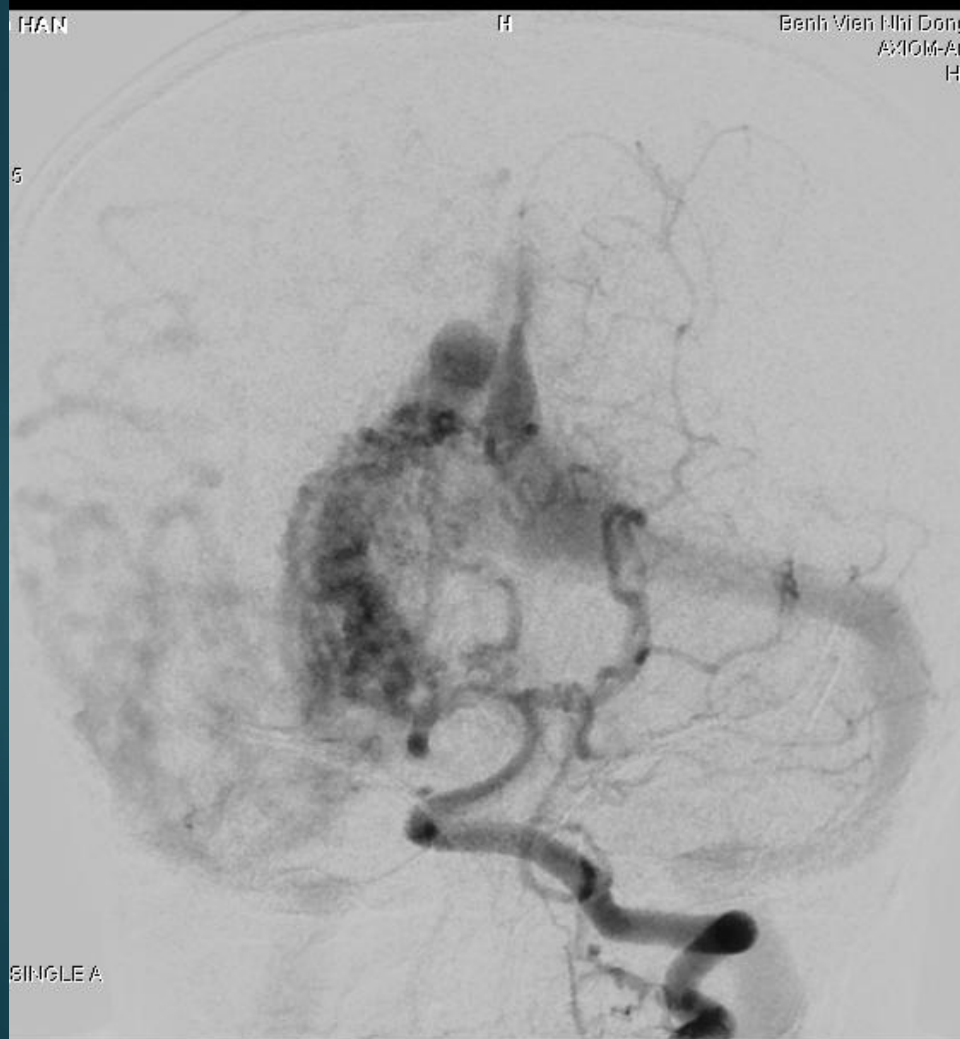
Endovascular treatment:

Embolic agents:

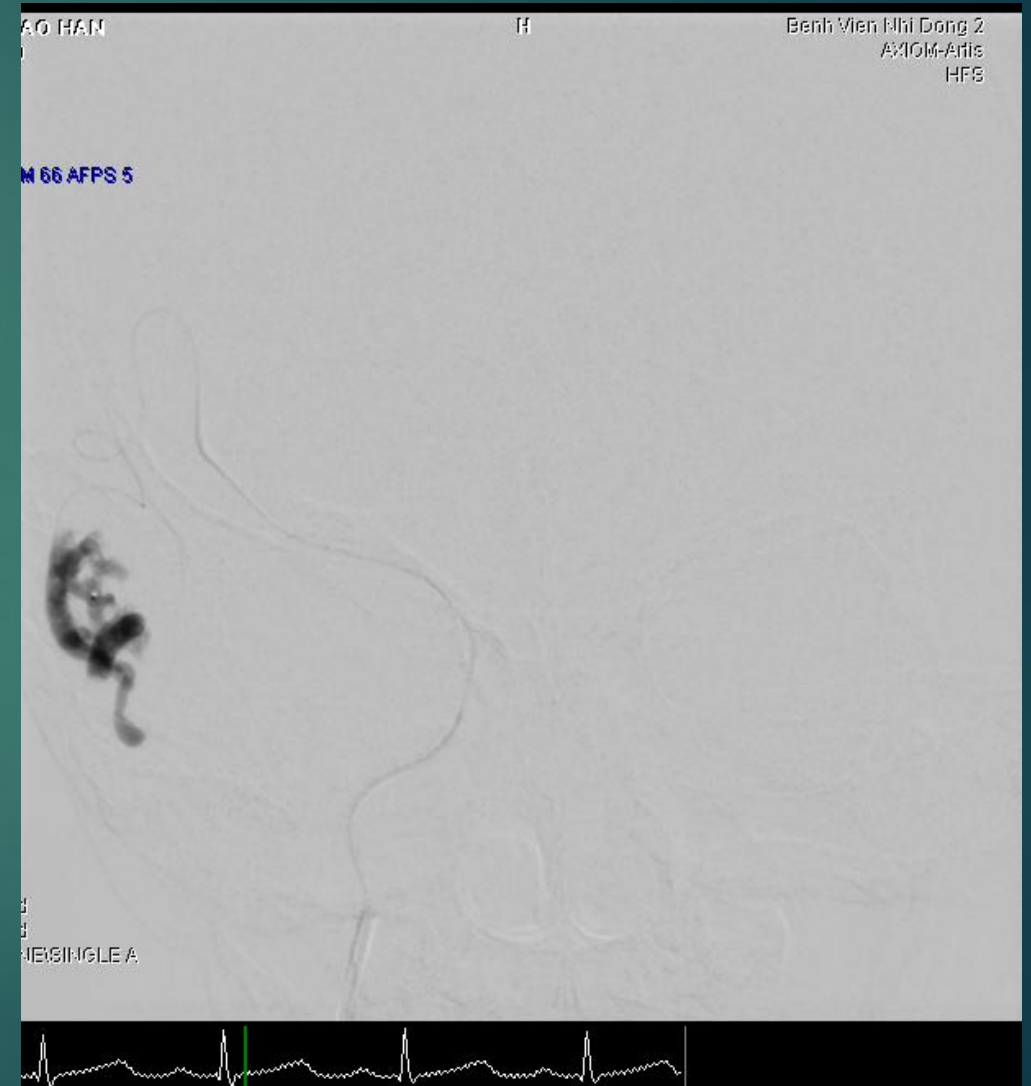
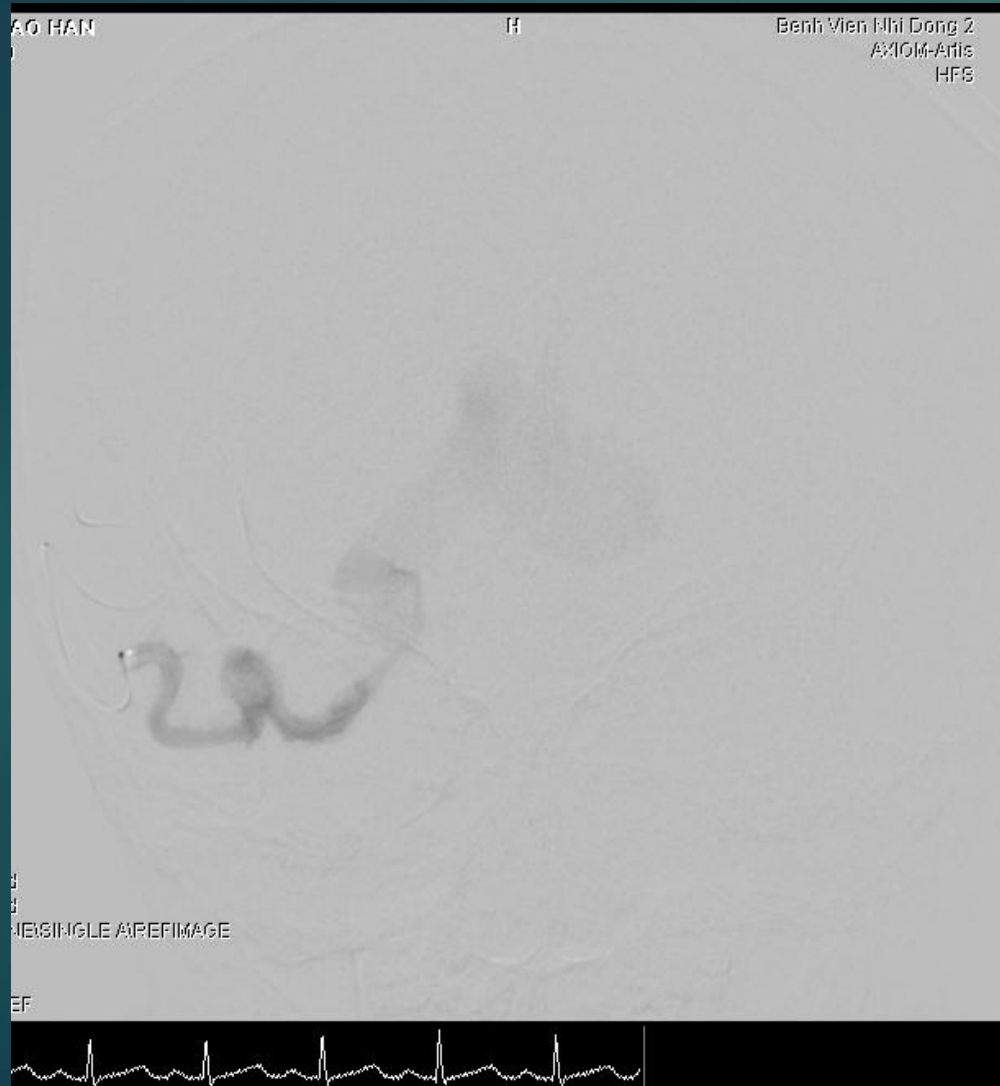- N-Butyl Cyanoacrylate
- Onyx
- Neuracryl M
-



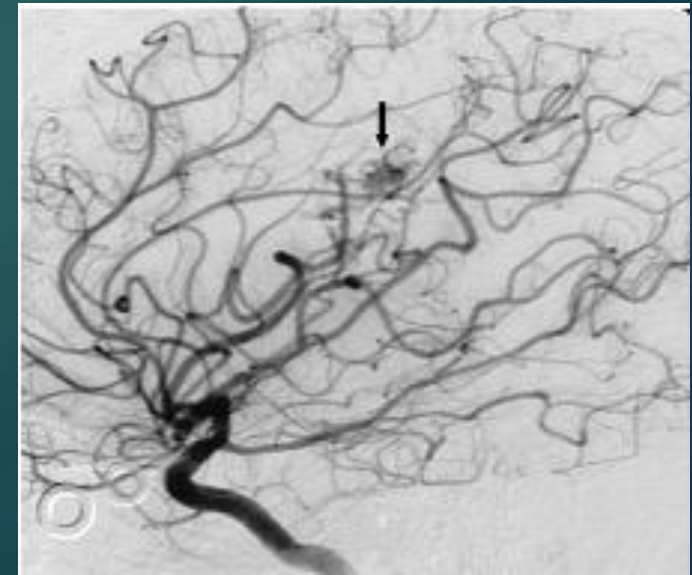
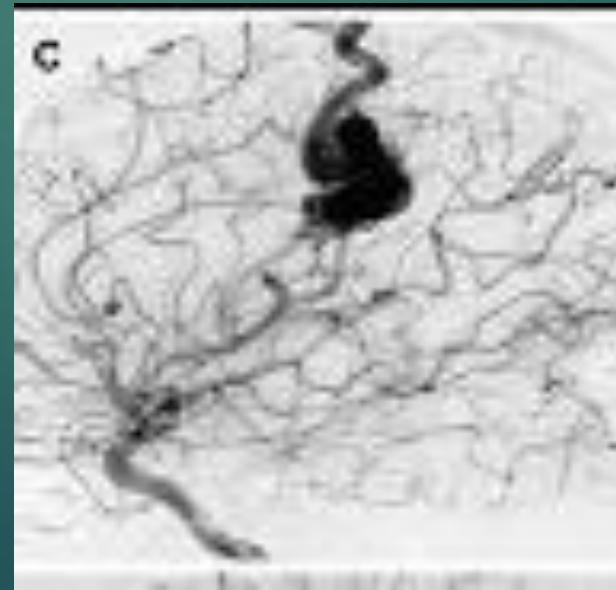
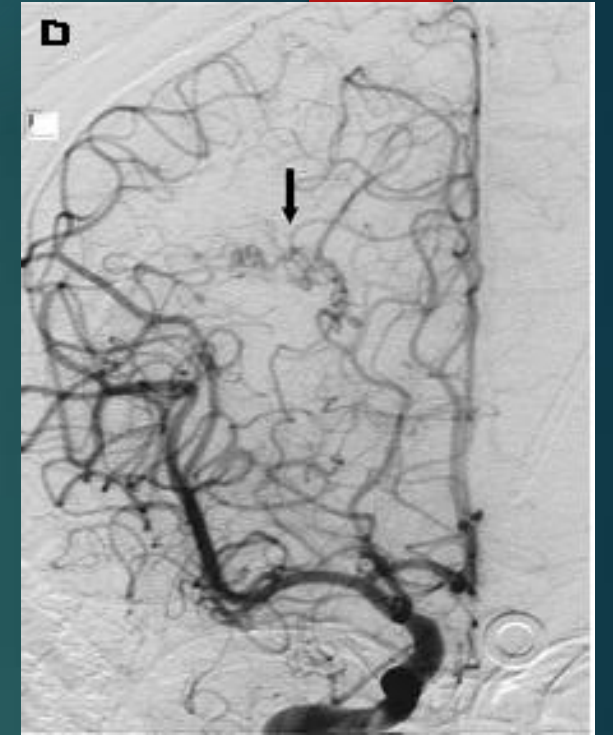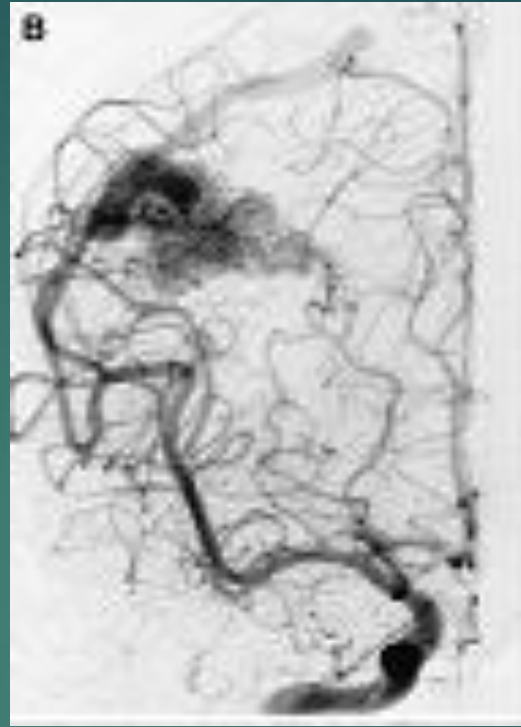
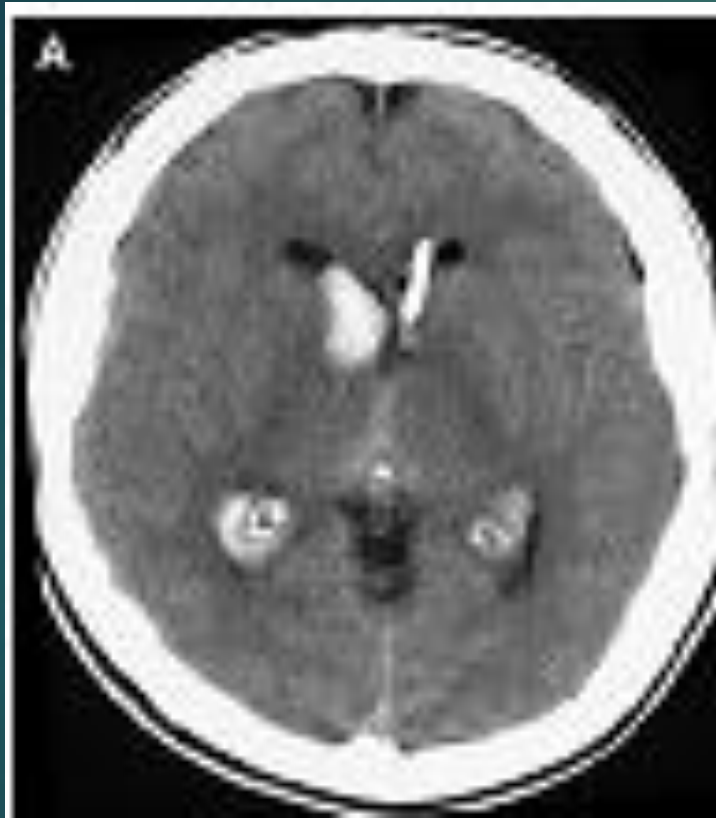Endovascular treatment:



Endovascular treatment:



Endovascular treatment:



Source: The role of neuroendovascular therapy for the treatment of brain arteriovenous malformations- Endovascular neurosurgery.

ASA guideline recommendations (2001)

- ▶ *Combined treatment with endovascular embolization followed by surgery may be used in patients with grade III lesions.*

ASA guideline recommendations (2001)

Treatment of aneurysms associated with AVMs varies depending on aneurysm location and diameter.

- ▶ *For feeding artery aneurysms >7 mm diameter, microsurgical clipping or endovascular coiling is suggested prior to treatment of the AVM.*

Treatment for brain arteriovenous malformation in the 1998–2011 period and review of the literature

- ▶ *Endovascular intervention should mainly be used for preoperative embolisation, as a curative procedure for lower-grade AVM in patients with comorbidities, and as palliation only for higher-grade cases.*

Clinical features and endovascular treatment of intracranial arteriovenous malformations in pediatric patients(2000-2012)

▶ Results: 127 patients ; 90/127 (70.9 %) hemorrhage,

Endovascular embolization: 66/127 patients (52 %)

Complete obliteration : 14/66 patients (21.2 %),

Volume reduction: 78 %

▶ Conclusions

Endovascular procedure is feasible and safe for pediatric AVMs, and complete embolization can be achieved in small AVMs, while large AVMs can be adequately reduced in size for additional microsurgery or stereotactic radiosurgery.

Complication:


- Microcatheter retention
- Ischemic complications
- Intracranial hemorrhage
- Hydrocephalus
- Seizure
-

▶ **Complication risk of endovascular embolization for cerebral arteriovenous malformation.**

<http://www.ncbi.nlm.nih.gov/pubmed/20950972>

▶ **CONCLUSIONS:**

Embolization of brain AVMs is safe, 95.9% of patients had excellent or good outcomes at discharge after AVM embolization using liquid embolic agents, with a complication rate of 4.8%.



- *Neuroendovascular embolization represents a critical component of the multidisciplinary management of cerebral arteriovenous malformations.*

- *Safe, effective procedure.*

References:

- Uptodate: Brain arteriovenous malformation.
- Pubmed
- American Stroke Association
- Endovascular Neurosurgery
- Intervetional Neuroradiology- Robert W. Hurst- Robert W. Rossenwasser.
- Textbook of Interventional Neurology – Adnan I. Qureshi

Thank you !

